



## Case Report

# Antiplatelet and invasive treatment in patients with glucose-6-phosphate dehydrogenase (G6PD) deficiency and acute coronary syndrome. The safety of aspirin

N. V. Kafkas MD PhD, C. I. Liakos MD PhD MSc and A. G. Mouzarou MD MSc  
Cardiology Department, 'KAT' General Hospital of Attica, 14561, Athens, Greece

Received 16 February 2015, Accepted 22 February 2015

**Keywords:** acetylsalicylic acid, acute coronary syndromes, angioplasty, aspirin, favism, Glucose-6-phosphate dehydrogenase (G6PD) deficiency

## SUMMARY

**What is known and objective:** Aspirin is an important drug in acute coronary syndromes (ACS) and percutaneous coronary interventions (PCI). However, its use is contraindicated in patients with glucose-6-phosphate dehydrogenase (G6PD) deficiency (risk for haemolytic anaemia). We report the management of 2 patients with class II G6PD deficiency and non-ST-segment elevation ACS (NSTEMI-ACS).

**Case description:** The two patients were safely and efficiently treated with dual antiplatelet treatment (DAPT, aspirin plus ticagrelor) and PCI using new-generation drug-eluting stent (DES) despite G6PD deficiency.

**What is new and conclusion:** NSTEMI-ACS management with DAPT and DES is probably safe and effective in class II G6PD-deficient patients.

## WHAT IS KNOWN AND OBJECTIVE

Glucose-6-phosphate dehydrogenase (G6PD) deficiency, also called favism, is a X-linked recessive disorder affecting 400 million people worldwide. The clinical expression of G6PD deficiency encompasses a spectrum of haemolytic syndromes. The majority of patients are asymptomatic, whereas some have episodic anaemia and few have chronic haemolysis. Favism presents with acute haemolytic anaemia after the ingestion of fava beans or the consumption of specific medication such as acetylsalicylic acid (ASA, aspirin).<sup>1–3</sup>

Aspirin is the cornerstone of the medication for acute coronary syndromes (ACS) or/and after percutaneous coronary intervention (PCI).<sup>4,5</sup> Treatment in such patients is particularly challenging when aspirin intake is contraindicated. G6PD deficiency is a case in which ASA treatment is generally contraindicated.<sup>6–8</sup>

We report on 2 patients with non-ST-segment elevation myocardial infarction (NSTEMI) successfully treated with dual antiplatelet treatment (DAPT, aspirin plus ticagrelor) and new-generation drug-eluting stent (DES) despite G6PD deficiency.

Correspondence: C. I. Liakos, 31 Stavraetou Street, 15772, Athens, Greece. Tel.: +30 6946246175; fax: +30 2132086312; e-mail: bliakos@med.uoa.gr

## CASE DESCRIPTION

### Case I

The first case refers to a 78-year-old Caucasian male, presenting with *de novo* resting angina, proved to be a NSTEMI. The patient had a known G6PD deficiency (with a history of acute haemolytic anaemia after eating fava beans) and an otherwise free medical history. His ECG showed sinus rhythm with negative T waves in leads I, aVL, V<sub>4</sub>–V<sub>6</sub>. The left ventricular (LV) lateral wall was hypokinetic on echocardiography, while the LV ejection fraction was 50%. Troponin levels were elevated.

### Case II

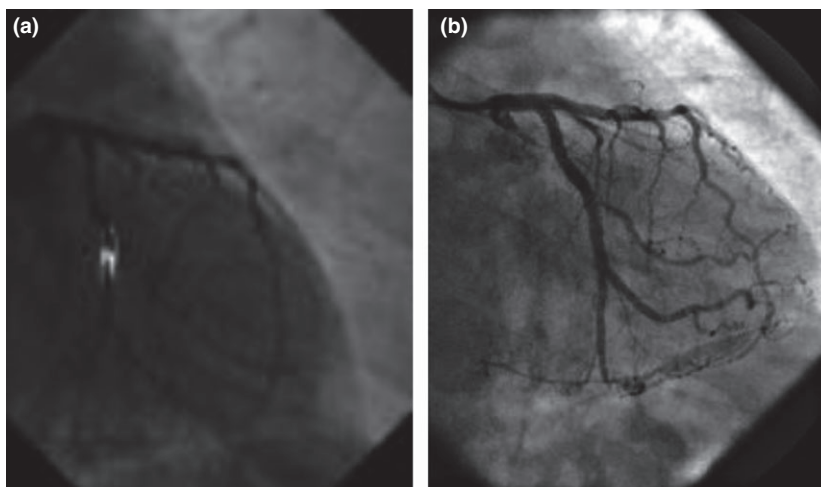
Our second patient, a 58-year-old Caucasian man, presented with *de novo* angina, also proved to be a NSTEMI. In his medical history, he reported arterial hypertension and G6PD deficiency (with an episode of acute haemolytic anaemia after eating fava beans). His ECG showed sinus rhythm with ST-segment depression in leads V<sub>2</sub>–V<sub>6</sub>. Antero-septal and apical LV wall hypokinesia was found on echocardiography with LV ejection fraction 45%. Troponin was elevated as well.

The management of the 2 cases was similar. All procedures were in accordance with the ethics standards of the institutional and/or national research committee and with the 1964 Helsinki Declaration and its later amendments or comparable ethics standards. Patients' G6PD enzyme levels were measured and were found low (2.6 and 0.8 U/g of haemoglobin in patients I and II, respectively). The residual G6PD enzyme activity was <10% of the normal in both cases. After taking into consideration the clinical symptoms, the geographic distribution (Mediterranean area – Greece) and the residual G6PD activity, our patients were classified as class II G6PD deficiency, according to the World Health Organization (WHO) categorization (Table 1).<sup>9</sup>

After consultation with the haematologist and discussion with the patients, an oral 100 mg daily dose of ASA (without a loading dose) was added to ticagrelor (180 mg loading dose, 90 mg twice daily maintenance dose) after an informed, written consent was obtained. Clinical symptoms (fatigue, back pain, jaundice and dark urine) as well as laboratory parameters (haemoglobin, reticulocyte count, unconjugated bilirubin and lactate dehydrogenase) suggestive of acute haemolytic crises were strictly monitored. Seventy-

**Table 1.** World Health Organization classification of G6PD genetic variants<sup>9</sup>

Class	Residual enzymatic activity	Clinical symptoms	Frequency & geographic distribution	Type of mutation
I	<1% or not detectable	Chronic haemolytic anaemia	Rare, without a precise geographic distribution	G6PD-Buenos Aires, G6PD-Durham
II	<10%	Acute haemolytic anaemia, fava beans and drug dependent	Frequent, distributed throughout the world	G6PD-Mediterranean, G6PD-Cassano, G6PD-Santamaria
III	10–60%	Occasionally acute haemolytic anaemia	Very frequent in malaria areas	G6PD-Seattle, G6PD-Canton, G6PD-Rignano
IV	60–90%	Asymptomatic	Undefined frequency	G6PD-Montalbano, G6PD-Orissa
V	>110%	Asymptomatic	Undefined frequency	Not reported

**Fig. 1.** Severe LCx stenosis before (a) and after (b) angioplasty in a right caudal view.

two hours after ASA administration, the patients did not present any symptoms or signs of haemolysis, and thus, an invasive management was decided, according to the European Society of Cardiology guidelines for the management of NSTEMI-ACS and for myocardial revascularization.<sup>4,5</sup>

A coronary angiography was performed with the radial approach. A severe stenosis in the left circumflex (LCx) artery was found in case I. A quantitative coronary angiography (QCA) was performed to confirm the visual estimation, and the narrowing was quantified up to 93% (Fig. 1a). A PCI followed, and a 3 × 12 mm zotarolimus-eluting stent (Resolute integrity, Medtronic, Minneapolis, USA) was successfully implanted (Fig. 1b). A severe stenosis in the left anterior descending (LAD) artery was found in case II (quantified up to 95% with QCA) (Fig. 2a). A 4 × 24 mm zotarolimus-eluting stent (Resolute integrity, Medtronic, Minneapolis, USA) was successfully implanted, as well (Fig. 2b).

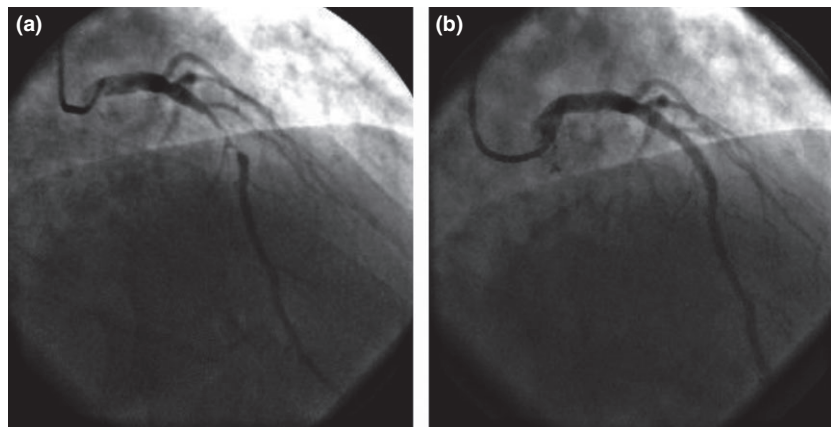
Symptoms or/and sign of haemolysis were monitored for 3 more days. As no clinical or laboratory evidence of acute haemolytic anaemia was present, the patients were discharged with the recommendation to continue DAPT over a year unless symptoms of haemolysis occur. In a monthly follow-up, patients

were free of symptoms (angina or haemolysis) 12 months after discharge. Aspirin was discontinued thereafter.

## DISCUSSION

The use of ASA is a cornerstone of treatment of patients with NSTEMI especially if revascularization with DES implantation is indicated. DAPT with ASA plus a P2Y12 inhibitor (ticagrelor or prasugrel or clopidogrel) is recommended for a 12-month period to reduce the risk of recurrent atherothrombotic events and stent thrombosis.<sup>4,5</sup> However, even high-risk patients are occasionally not treated with ASA because of active gastric disease or hypersensitivity reaction, although the latter can be successfully overcome with desensitization protocols.<sup>10</sup> G6PD deficiency is another situation in which ASA treatment is generally contraindicated.<sup>6–8</sup>

The severity of G6PD deficiency and the risk of haemolysis depend on the residual enzyme activity which is determined by the characteristics of the G6PD variant (Table 1). There is a wide and heterogeneous group of mutations that may lead to different extents of reduction of enzyme activity in RBCs. Normal values of G6PD levels differ according to the methodology employed and



**Fig. 2.** Severe LAD stenosis before (a) and after (b) angioplasty in a right cranial view.

are related to the temperature (25, 30 or 37 °C) at which the assays are performed. They range from 5.5 to 8.8 and from 8.8 to 20.5 U/g of haemoglobin for the lower and the upper limit of normal, respectively.<sup>9</sup>

The enzyme deficiency is a necessary but not sufficient condition for haemolytic crisis. The latter is clinically expressed in the presence of oxidative stress induced for example by oxidant drugs, fava beans or systemic infections.<sup>6,8</sup> In particular, several drugs are known to be responsible for inducing haemolysis in such patients (Table 2).<sup>1</sup> Other drugs have more minor effects on RBCs survival. Drugs such as ASA, when given in large doses, in particularly sensitive patients or when combined with other oxidant agents can also induce a haemolytic crisis.<sup>8</sup> Thus, a usually benign genetic disease can occasionally become life threatening in the presence of triggers which affect the clinical phenotype. The intensity of oxidative stress, the biochemical properties of the variant enzyme and the age or/and the clinical condition of the patient are influential.<sup>1-3,6-8</sup>

There are only a few reports on the long-term safety of ASA in patients with favism.<sup>11</sup> Moreover, reports are even fewer regarding the long-term safety and efficacy of DAPT in patients with G6PD deficiency needing PCI with DES, and thus, no official guidelines are available.<sup>12,13</sup>

The limited data available on the safety of ASA in patients with favism and ACS are rather contradictory. Porto *et al.*<sup>12</sup> describe a case of anterior STEMI treated in the acute phase using manual thrombectomy and intracoronary IIb/IIIa glycoprotein inhibition with abciximab without any attempt to implant a stent. Seven days later, a repeat angiography showed a Thrombolysis in Myocardial Infarction (TIMI) grade 3 flow and the presence of an intermediate proximal LAD lesion which was not treated due to the existing history of G6PD deficiency and 'loss of consciousness' at a younger age after taking aspirin. Rigattieri *et al.*<sup>13</sup> describe a case of acute inferior myocardial infarction in a patient with G6PD deficiency. Aspirin was not given in the acute phase, and the patient was successfully treated with balloon angioplasty of the right coronary artery. After functional and genetic testing showing the presence of the Mediterranean mutation, known to be a class II variant (Table 1), the patient received oral daily aspirin (100 mg) under strict monitoring. A complex PCI with 2 DES in the left coronary artery followed 4 days later. Three months later, the patient was free from adverse events. In an historical review article, Beutler *et al.*<sup>1</sup> reported that there are drugs and chemicals that should be avoided in G6PD-deficient patients, but also there are some

**Table 2.** Safety of various drugs and chemicals in G6PD deficiency<sup>1</sup>

Unsafe for class I, II and III variants	Safe for class II and III variants <sup>a</sup>
Acetanilid	Acetaminophen
Dapsone	Aminopyrine
Methylene blue	Ascorbic acid (except in very high doses)
Nalidixic acid	<b>Acetylsalicylic acid (aspirin)</b>
Naphthalene	Chloramphenicol
(mothballs, henna)	Chloroquine
Niridazole	Colchicine
Nitrofurantoin	Diphenhydramine
Phenazopyridine	Isoniazide
Phenylhydrazine	L-DOPA
Primaquine	Menadiione
Sulphacetamide	Paraaminobenzoic acid
Sulphamethoxazole	Phenacetin
Sulphanilamide	Phenytoin
Sulphapyridine	Probenecid
Thiazosulphone	Procainamide
Toluidine blue	Pyrimethamine
Trinitrotoluene	Quinidine
Urazolidone	Quinine
Uricase	Streptomycin
	Sulphamethoxypyridazine
	Sulphisoxazole
	Trimethoprim
	Tripelennamine
	Vitamin K

<sup>a</sup>Safety for class I variants is usually not known.

commonly used drugs that can be safely administered in therapeutic doses in patients without non-spherocytic haemolytic anaemia (Table 2).

Finally, patients with G6PD deficiency in the Mediterranean region who are asymptomatic with no signs of chronic haemolysis have a very high probability of carrying the Mediterranean mutation and belong to class II (WHO classification, Table 1). As the incidence of Mediterranean mutation is very high in G6PD-deficient patients living in South Europe (Mediterranean region),

ASA administration is probably safe in these patients especially if close monitoring for signs of haemolysis (jaundice, pallor, dark urine, abdominal and back pain, abrupt fall in the haemoglobin concentration of 3–4 g/dL) can be assured.

Our decision to use a DES over a bare metal stent was based upon studies showing better long-term prognosis.<sup>5</sup> Besides, the 72-h monitoring of the patients prior to the angioplasty provided sufficient evidence that DAPT could be maintained over a year. The choice of a new-generation DES (zotarolimus) provided us with the alternative of a shorter DAPT if that emerged as necessary during the 12-month follow-up.<sup>5</sup>

## WHAT IS NEW AND CONCLUSION

The management of NSTEMI-ACS with DAPT and a new-generation DES is probably safe and effective in patients with class II G6PD deficiency.

## CONFLICT OF INTEREST DISCLOSURE STATEMENT

All authors declare that they have no conflicts of interest.

## REFERENCES

1. Beutler E Glucose-6-phosphate dehydrogenase deficiency: a historical perspective. *Blood*, 2008;**111**:16–24.
2. Cappellini MD, Fiorelli G Glucose-6-phosphate dehydrogenase deficiency. *Lancet*, 2008;**371**:64–74.
3. Mason PJ, Bautista JM, Gilsanz F G6PD deficiency: the genotype-phenotype association. *Blood Rev*, 2007;**21**:267–283.
4. Hamm CW, Bassand JP, Agewall S *et al.* ESC Guidelines for the management of acute coronary syndromes in patients presenting without persistent ST-segment elevation: The Task Force for the management of acute coronary syndromes (ACS) in patients presenting without persistent ST-segment elevation of the European Society of Cardiology (ESC). *Eur Heart J*, 2011;**32**:2999–3054.
5. Windecker S, Kolh P, Alfonso F *et al.* 2014 ESC/EACTS Guidelines on myocardial revascularization: The Task Force on Myocardial Revascularization of the European Society of Cardiology (ESC) and the European Association for Cardio-Thoracic Surgery (EACTS) developed with the special contribution of the European Association of Percutaneous Cardiovascular Interventions (EAPCI). *Eur Heart J*, 2014;**35**:2541–2619.
6. Meloni T, Forteleoni G, Ogana A, Franca V Aspirin-induced acute haemolytic anaemia in Glucose-6-phosphate dehydrogenase deficient children with systemic arthritis. *Acta Haematol*, 1989;**81**:208–209.
7. Colonna P Aspirin and Glucose-6-phosphate dehydrogenase deficiency. *Br Med J (Clin Res Ed)*, 1981;**283**:1189.
8. Stockman JA, Lubian B, Oski FA Aspirin-induced hemolysis: the role of concomitant oxidant (H<sub>2</sub>O<sub>2</sub>) challenge. *Pediatr Res*, 1978;**12**:927–931.
9. Minucci A, Giardina B, Zuppi C, Capoluongo E Glucose-6-phosphate dehydrogenase laboratory assay: how, when and why? *IUBMB Life*, 2009;**61**:27–34.
10. Christou A, Kafkas N, Marinakos A, Katsanos S, Papanikitas K, Patsilnakos S Rapid desensitisation of patients with aspirin allergy who undergo coronary angioplasty. *Hellenic J Cardiol*, 2011;**52**:307–310.
11. Shalev O Long-term, low-dose aspirin is safe in glucose-6-phosphate dehydrogenase deficiency. *DICP*, 1991;**25**:1074–1075.
12. Porto I, Leo A, Crea F Glucose-6-phosphate dehydrogenase (G6PDH) deficiency in a patient with ST-Segment elevation acute myocardial infarction successfully treated by simple thrombectomy. *J Atheroscler Thromb*, 2011;**18**:425–430.
13. Rigattieri S, Silvestri P, Minucci A *et al.* Drug-eluting stents in a patient with favism: is the aspirin administration safe? *J Cardiovasc Med (Hagerstown)*, 2008;**9**:1159–1162.